

The autistic brain: birth through adulthood

Eric Courchesne^{a,c}, Elizabeth Redcay^b and Daniel P. Kennedy^a

Purpose of review

We discuss evidence of brain maldevelopment in the first years of life in autism and new neuroanatomical and functional evidence from later ages of development.

Recent findings

Head circumference, an accurate indicator of brain size in children, was reported to jump from normal or below normal size in the first postnatal months in autistic infants to the 84th percentile by about 1 year of age; this abnormally accelerated growth was concluded by 2 years of age. Infants with extreme head (and therefore brain) growth fell into the severe end of the clinical spectrum and had more extreme neuroanatomical abnormalities. In the frontal and temporal lobes in autism, there have been reports of abnormal increases in gray and white matter at 2 to 4 years; reduced metabolic measures; deviant diffusion tensor imaging results in white matter; underdeveloped cortical minicolumns; and reduced functional activation during socio-emotional, cognitive and attention tasks. Cerebellar abnormalities included abnormal volumes, reduced number and size of Purkinje neurons in the vermis and hemispheres, molecular defects, and reduced functional activation in posterior regions.

Summary

A new neurobiological phenomenon in autism has been described that precedes the onset of clinical behavioral symptoms, and is brief and age-delimited to the first two years of life. The neurobiological defects that precede, trigger, and underlie it may form part of the developmental precursors of some of the anatomical, functional, and behavioral manifestations of autism. Future studies of the first years of life may help elucidate the factors and processes that bring about the unfolding of autistic behavior.

Keywords

autism, brain growth, development, neuroimaging, head circumference, MRI, fMRI, postmortem

Curr Opin Neurol 17:489–496. © 2004 Lippincott Williams & Wilkins.

Departments of ^aNeurosciences, and ^bPsychology, University of California, San Diego, California, USA; and ^cCenter for Autism Research, Children's Hospital Research Center, San Diego, California, USA

Correspondence to Eric Courchesne, Center for Autism Research, 8110 La Jolla Shores Drive, Suite 201, San Diego, CA 92037, USA
Tel: +1 858 551 7925; e-mail: ecourchesne@ucsd.edu

Current Opinion in Neurology 2004, 17:489–496

Abbreviations

ASD	autism spectrum disorder
DTI	diffusion tensor imaging
HC	head circumference
MRI	magnetic resonance imaging
MRS	magnetic resonance spectroscopy
PDD–NOS	pervasive developmental disorder not otherwise specified

© 2004 Lippincott Williams & Wilkins
1350-7540

Introduction

Autism is a behaviorally defined disorder clinically characterized by social deficits, language impairments, and restricted and repetitive behaviors and interests [1,2]. Research has revealed additional abnormalities in sensory, motor, attention, memory, speech, exploring novelty and many other areas of behavioral and cognitive functioning [3].

Autism is most often first clinically recognized and diagnosed at between 2 and 4 years of age. However, parental comments, single case reports, and retrospective studies suggest that subtle motor, sensory, attention and social behavioral abnormalities may often be present, but clinically overlooked, during the first or second years of life [4–7]. Neural maldevelopment must underlie and precede these early autistic behavioral abnormalities, but little is known about defects and abnormal processes at this very early age.

By contrast, studies of older children and adults have provided magnetic resonance imaging (MRI), functional MRI, and postmortem evidence of cerebral, cerebellar, and limbic abnormalities [3,8–11]. Therefore, although autism is clearly understood to be a disorder of early brain development, until recently there has been a large gap in the knowledge about its origins, and therefore about whether or not findings on older patients reflect early maldevelopmental processes.

In the past few years, studies have helped to fill this gap by providing information about brain growth abnormalities within the first years of life in autism. In this review, we place these new results into the context of recent neuroimaging studies of autism at later ages, thereby providing a first look at aspects of brain maldevelopment from birth to adulthood in this disorder. Consistent patterns of neural maldevelopment are observed, and hypotheses and new evidence regarding defects underlying growth abnormalities are discussed.

Brain growth abnormality from birth to adulthood in autism

Brain development in autism from 2 years of age onward has been the subject of recent MRI studies, as we discuss below. However, because autism is not typically clinically recognized before 2 to 4 years of age, no neuroimaging evidence exists regarding brain growth abnormality from birth to 2 years of age. Fortunately, records of age-related changes in head circumference (HC) from birth can provide clues about brain growth

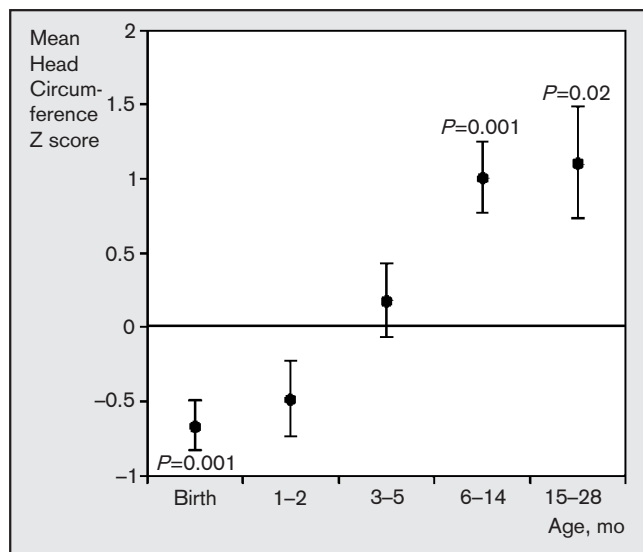
during these first two years of life. Studies of the correlation between HC and MRI brain volume have shown that HC in young autistic and normal children is an accurate index of brain volume, although it is a poor index of brain volume at progressively older ages [12]. HC measures thus offer an opportunity to assay brain growth in autism at early ages.

A process of brain overgrowth in the first two years of life

Longitudinal changes in HC during the first 2 years of life were analyzed in a sample of autism spectrum disorder (ASD) patients that included both autistic disorder (the severe end of the spectrum) and pervasive developmental disorder not otherwise specified (PDD-NOS; the mild end) patients [13••]. Compared with the Centers for Disease Control and Prevention HC norms, HC in the ASD groups was at the 25th percentile at birth and then increased rapidly to the 84th percentile by 6–14 months of age (Fig. 1). This period of abnormally accelerated HC increase, and therefore brain growth, was apparently largely concluded before the end of the second year of life (Fig. 1).

The same study also reported that those at the more severe end of the spectrum, the autistic disorder infants, had a substantially greater rate and amount of HC

Figure 1. Age-related changes in head circumference during infancy in autism spectrum disorder



At birth and at 1–2 months of age, head circumference in a longitudinal autism spectrum disorder group was statistically significantly below the Centers for Disease control and Prevention (CDC) mean for healthy infants, but by 6–14 months of age, it was more than 1.0 SD (84 percentile) above the mean for healthy infants. The CDC mean of healthy infants at each age is 0. Error bars are SEM. Reproduced with permission from Courchesne *et al.* [13••].

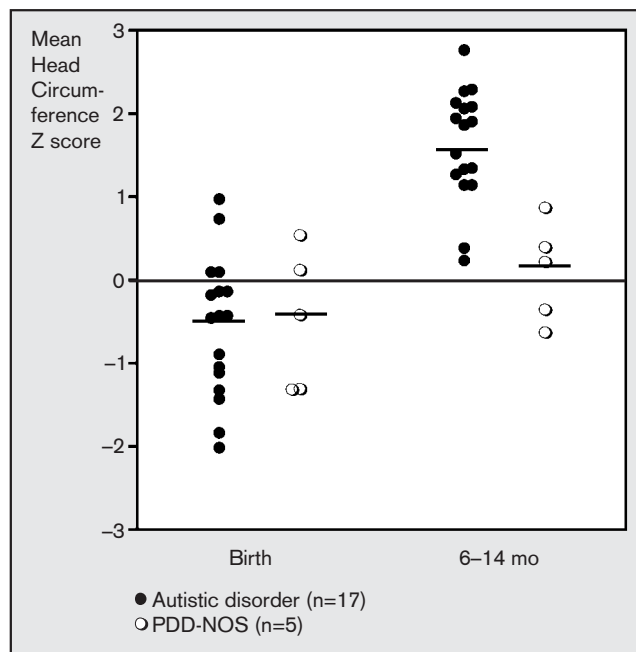
increase than the PDD-NOS infants (Fig. 2). This is consistent with a previous prediction [14] that brain overgrowth may be earlier, more rapid and more substantial in more severely affected autistic children. Moreover, the study reported that in their ASD group, brain size at birth and overgrowth by the end of the first year of life were strongly correlated with abnormal cerebellar and cerebral volumes, respectively, at 2–5 years of age.

This evidence indicates a process of early, brief and age-limited brain overgrowth in autism during the first two years of life. To our knowledge, this is the first evidence of brain maldevelopment in process before the overt clinical behavioral manifestation of the disorder. Further studies will be needed to delineate the ages of onset, peak, and cessation of this process more precisely.

Neuroanatomical abnormalities at 2–5 years of age

By 2 to 3 years of age, 90% of autistic toddlers had brain volumes that exceeded normal average toddlers; cerebral gray and white matter and cerebellar white matter volumes were abnormally large [14]. This first report of

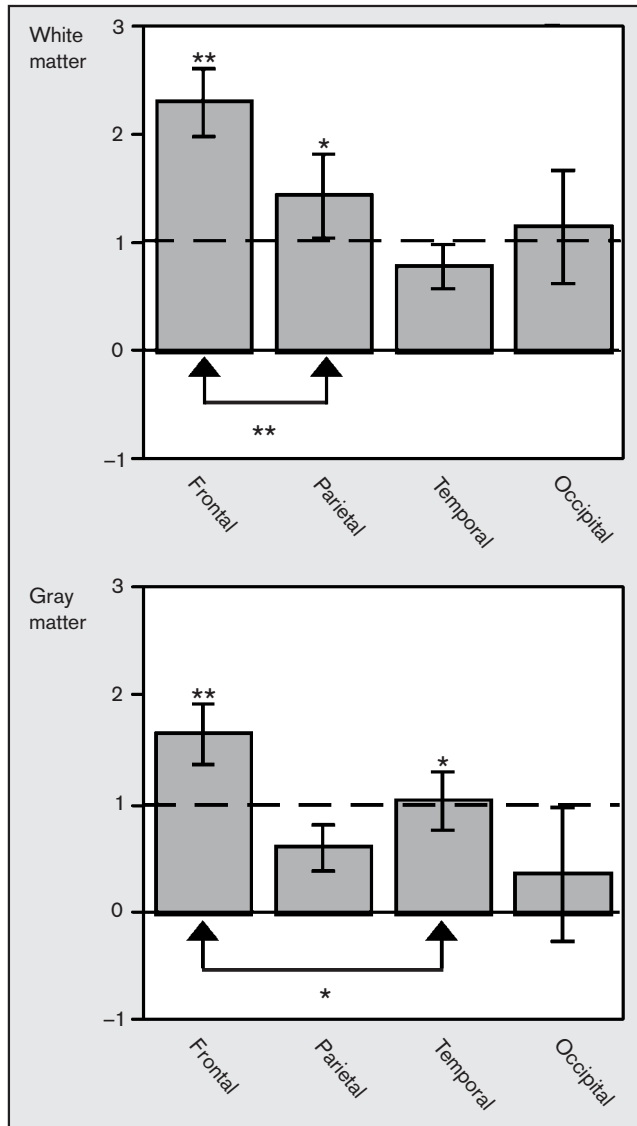
Figure 2. Increase in head circumference from birth to 6–14 months of age between infants with Autistic Disorder and infants with PDD-NOS



PDD-NOS indicates pervasive developmental disorder not otherwise specified. At each age and for each group, short horizontal bars indicate mean head circumference. The infants with Autistic Disorder (closed circles; n=17) had a greater rate of growth in head circumference between birth and 6–14 months of age than did those with PDD-NOS (open circles; n=5). Reproduced with permission from Courchesne *et al.* [13••].

brain and cerebral enlargement in young children was recently replicated in an independent study of 3–4-year-old autistic and normal children which also found larger than normal volumes of whole brain, cerebrum, and cerebellum and additionally found amygdala enlargement [15].

Figure 3. In autistic 2–4-year-old children frontal lobes have the most abnormal enlargement of white and gray matter volumes



For each white and gray matter region, volumes were converted to z-scores for each 2–4-year-old autistic child based on the means and standard deviations of normal children of the same age. '0' on the y-axis indicates the normal mean and y-axis values indicate z-scores above this normal mean. Among autistic 2–4-year-old children, frontal and parietal white matter volumes and frontal and temporal gray matter volumes were each significantly larger (asterisks) than normal. Error bars are standard error of the mean for autistic children.

Reproduced with permission from Carper *et al.* [16].

By 2 to 4 years of age, autistic children had the most extreme enlargement of gray and white matter volume in frontal and temporal lobes; white matter abnormality was maximal in the frontal and parietal lobes (Fig. 3) [16]. In contrast, the occipital lobes were not significantly enlarged. Consistent with this differential enlargement of the frontal and temporal gray matter, an MRI sulcal mapping study of autistic preadolescents showed anterior and superior shifting of several sulci, with the greatest deviations from normal being the superior frontal, inferior frontal, and superior temporal sulci and the Sylvian fissure [17].

Cerebellar maldevelopment is certain, but complex. By 2 to 4 years of age in autistic children, cerebellar gray matter volume was not enlarged, and lobules VI–VII of the posterior vermis were actually reduced [14]. Surprisingly, however, the same study reported cerebellar white matter volume to be a dramatic 39% greater than the normal average [14]. The cerebellum thus had an abnormally small ratio of gray to white matter, raising the possibility that aberrant axonal projections into the cerebellum mark early life in autism, and may be related to Purkinje neuron loss.

In the largest autism study of the cerebellar vermis, Hashimoto *et al.* [18] reported cerebellar vermis hypoplasia in autism from infancy to adolescence. In a study of 3–9-year-old children, a reduced size of the cerebellar vermis lobules VI–VII alone was found to be specific to autistic children compared with other normal, fragile X, fragile X with autism, Down syndrome, and Down syndrome with autism children [19]. In another study of 9–16-year-old children, vermis lobules VIII–X were significantly reduced in the autism group [20]. The findings in these several studies appear to be compatible with postmortem evidence of pervasive cerebellar pathology, which includes Purkinje neuron loss in the vermis and/or hemispheres in over 95% of all cases [8], reductions in the concentrations of one anti-apoptotic protein [21,22] and abnormalities in nicotinic receptors [23].

Interestingly, evidence suggests that increased frontal volumes and decreased cerebellar vermal volumes may be linked. Children with autism, aged 3–9 years, showed an inverse linear relationship between these two structures; a relationship not seen in typically developing children [24]. The authors proposed that frontal overgrowth may be a result of excessive excitatory output from the cerebellum, a consequence of reduced inhibitory Purkinje cell input to deep cerebellar nuclei.

Neuroanatomical abnormalities are so substantial that analyses using discriminant function have shown that factors representing cerebellar and cerebral volumes

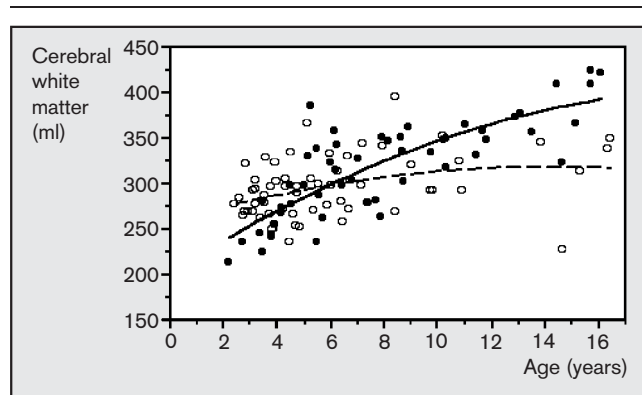
(especially cerebellar and cerebral white matter volumes and cerebellar vermis size) were 95% accurate in discriminating autistic from normal 2–5-year-old children [25].

Later stages of development and maturation of the autistic brain

After this early developmental period marked by accelerated growth and excess size in many structures in young autistic children, the neural landscape changes. Sometime between 5 and 12 years of age the autistic brain is no longer significantly larger than normal. Seven recent MRI studies have reported no significant difference from normal in autistic brain volume at ages 5–13 years [26], 7–11 years [27], 5–16 years [14], 8–45 years [28], 10–38 years [29*], 19–47 years [30] and 12–46 years [31]. One study reported slightly larger (4%) than normal brain volumes at ages 8–12 years [31]. Furthermore, most previous studies of older autistic children, adolescents and adults reported either smaller brain volumes or no significant difference from normal [32–37]. A meta-analysis of all autism autopsy brain weights in the literature showed normal average weight in 18 of 21 cases, and macrencephaly in 3 of those 21 cases [38].

In the first cross-sectional MRI study of autism from early childhood to maturation, cerebral white matter was excessive in 2–3-year-olds but thereafter increased at an abnormally reduced rate (11% between 2–3 and 12–16 years in autism vs 59% in normal controls; see Fig. 4), suggesting that autism involves abnormal as well as reduced cerebral axonal connections [14]. Abnormally slowed growth during later childhood was most evident

Figure 4. Cerebral white matter volume is abnormally increased in younger autistic children but not in autistic adolescents



Volumes of cerebral white matter are plotted for individual 2–16-year-old autistic (open circles) and normal (closed circles) subjects along with best-fit growth curves (autism is dashed line; normal is solid line). Among autistic subjects, cerebral white matter volume was greater than normal between 2 and 4 years of age but not at older ages. Reproduced with permission from Courchesne *et al.* [14].

in frontal and temporal white matter and least in occipital [16]. Decreased rates of growth during these same years were also seen in gray matter in autism [14]. For example, whereas in normal controls cerebral gray matter volume increased 12% between 2–3 and 6–9 years of age cerebral gray matter volume actually decreased slightly (–2%) in autistic children [14].

Other recent studies find either normal or reduced volumes in limbic or cerebral structures by later childhood, adolescence or adulthood in autism [14,26,27,39–41]. One of these studies reported greater than normal cerebral gray but not white volumes in autistic adolescents [39], while another reported greater than normal cerebral white but not gray volumes in 7–11-year-old autistic subjects [27]. In follow-up analyses of the same subjects in the latter study, a recent study reported greatest white matter volume abnormality immediately underlying cortex, with white matter underlying frontal cortex showing the greatest deviation from normal [42]. In contrast, increased volume did not occur in white matter containing long distance connections such as callosal and anterior-posterior projections.

A general pattern is thus emerging in the autism literature: The early childhood period of excessive growth is replaced sometime during middle to late childhood by a period of relatively slowed growth in the brain overall, as well as in the cerebrum, cerebellum, and limbic system.

Brain growth abnormality: etiological origins, neural bases and functional consequences

Genetic and non-genetic factors involved in the etiology of early brain overgrowth in autism have recently been pursued. In a recent study examining genetic contributions to enlarged HC in autism, an association was found between a HOXA1 polymorphism and this endophenotypic measure [43]. Whereas the HOXA1 polymorphism was only able to account for 5% of the variance in autistic HC, the study used HC as measured at ages 3–33 years, and HC at these ages is not a sensitive measure of the degree of early brain growth abnormality. More sensitive endophenotypic measures in future studies would be, for example, the rate and magnitude of HC change from birth through the first two years of life. In addition, a large number of genes are plausible as participants in the production of early brain overgrowth in autism. Immediately obvious candidates include BDNF, VIP and other neural growth factors reported to be elevated in blood samples in neonates who were later diagnosed as autistic [44].

Strong evidence has been reported for an association between autism and the EN2 gene, a cerebellar patterning gene [45]. EN2 mouse mutants have abnor-

mal postnatal cerebellar development and defects which are 'reminiscent' of several of those reported for the cerebellum in autism [8,23,46,47]. It is important for future studies to determine whether these mutants also show other characteristics of the abnormally developing autistic cerebellum, such as early overgrowth of white matter and reduced gray to white matter ratio. The importance of cerebellar abnormality in autism is further accentuated by the new finding that among monozygotic twins of which one has autism, discordance for autism is paralleled by discordance in cerebellar, but not cerebral, anatomical volumes [26], as well as by numerous previous studies showing a role for the cerebellum in perception, attention, memory, language, novelty exploration and emotion [3,48–51].

Pre- and postnatal viral etiologies have also been proposed for autism. Neonatal rats infected with Borna disease virus show neurobehavioral disturbances in sensorimotor, emotional, and social activity [52]. Further, these animals show loss of cerebellar granule and Purkinje neurons as well as loss of pyramidal neurons of layers V and VI in cingulate and retrosplenial cortices [52]. Patterson [53] hypothesized that when a pregnant mother is infected with influenza, fetal brain maldevelopment and subsequent behavioral abnormalities can be caused by the maternal antiviral immune response. In tests of this specific hypothesis, a series of studies [54•,55•] demonstrated that prenatal influenza exposure in mice resulted in smaller brain sizes at birth, but macrocephaly in adulthood, thus mirroring the pattern of neonatal undergrowth and then overgrowth seen in autism. Furthermore, the mice have altered pyramidal and non-pyramidal cell densities, and underdeveloped pyramidal cells [54•]. Affected animals also showed some of the categories of behavioral abnormalities present in autism, including reduced social interactions, reduced exploration, and deficits in prepulse inhibition. Interestingly, evidence suggests that triggering the inflammatory response alone may be sufficient to produce the observed behavioral abnormalities [55•].

In an effort to determine the neural underpinnings of early brain overgrowth in autism, a recent study by Friedman *et al.* used magnetic resonance spectroscopy (MRS) to test the hypothesis that the overgrowth is caused by increased neural and synaptic density (perhaps because of reduced apoptosis and pruning) [56•]. They measured *N*-acetylaspartate in autistic 4-year-olds who in a previous MRI study had been shown to have abnormally large brain volumes [15]. The authors expected to find in these autistic children evidence suggestive of increased neuronal and/or synaptic density, namely increased *N*-acetylaspartate with shortened T2 relaxation times. Contrary to their hypothesis, *N*-acetylaspartate concentrations were re-

duced and relaxation times were prolonged in various cerebral regions, consistent with reduced neuron or synaptic density or integrity. The regions of reduced *N*-acetylaspartate included the cingulate, right thalamus, right superior temporal gyrus, and left frontal and right parietal white matter. Another MRS study of the older autistic brain (5–16 years) also found either normal or reduced, but not increased, *N*-acetylaspartate throughout the cerebrum; regions of reduction included the left frontal and parietal white matter and caudate body [57]. Previous studies of autistic children and adults also reported *N*-acetylaspartate reductions, not increases, in temporal areas 41 and 42 [58], hippocampus and amygdala [59], and cerebellum [59,60]. MRS studies in autism have thus found a consistent picture of reduced *N*-acetylaspartate in the cerebellum and limbic system and either reduced or normal *N*-acetylaspartate in frontal and temporal lobes, all regions known from volumetric and postmortem studies to have significant brain maldevelopment. *N*-acetylaspartate findings to date do not support the hypothesis of increased neural and synaptic density as the basis for early brain overgrowth in autism.

In histological analyses of the brains from autistic children and adults, reduced neuron density as well as small and underdeveloped cortical minicolumns have been described in frontal area 9 and temporal areas 21 and 22 [61]. These findings would seem to be compatible with the findings of reduced *N*-acetylaspartate and prolonged chemical relaxation times in MRS studies of autism. Casanova *et al.* [61] speculated that the cortex in autism might have abnormally reduced thalamic signaling as well as reduced lateral inhibitory control, both connectivity aberrations that could result in neural processing 'noise'. Interestingly, an MRI volumetric study [29•] reported that autistic children have a smaller than expected ratio of thalamic to whole brain volumes, raising the question of whether autism may involve a mismatch in the number of thalamocortical afferents and the number of minicolumns.

Connectivity patterns must be abnormal in some fashion in autism, given the above observations regarding MRI and postmortem evidence of maldevelopment in cerebral and cerebellar gray and white matter, and MRS abnormalities reported for frontal and parietal white matter. Diffusion tensor imaging (DTI) is an MRI method that provides information about the direction of water diffusion in white matter. Results from a preliminary DTI study comparing autistic and normal adolescents [62•] showed abnormalities in multiple cerebral white matter areas, including regions within the frontal and temporal lobes, the temporo-parietal junction, and corpus callosum. This evidence suggests the possibility that the same regions that

experience the greatest amount of early overgrowth also show the greatest aberrations in white matter. Whereas these results are not measures of connectivity *per se*, they add to the MRS and volumetric MRI evidence of cerebral white matter abnormality in autism. The next step of actually deriving accurate connectivity maps in this disorder will probably be challenging, but critical to do.

Functional MRI provides a macroscopic test of normalcy of regional involvement in processing information. There have been few functional MRI studies of autism, and many have used small samples with a mixture of autistic and Asperger patients, which precludes disorder-specific conclusions. Nonetheless, studies have generally identified reduced functional activation in higher-order cortices, paralleling areas of abnormality in MRI, MRS, DTI, and postmortem studies. For example, in a visual selective attention task, frontal cortical activations were abnormally reduced in patients, but occipital cortical activations were normal or even greater than normal [63•]. In a series of face and visual search tasks, the most pronounced deviation from normal in the patients was underactivation in the dorsal frontal areas during the search tasks [64]. During a mentalizing task, autistic subjects showed reduced medial frontal and superior temporal activity but normal extrastriate activity as compared to controls [65]. In autistic patients, superior posterior cerebellar activation during a visual selective attention task was abnormally reduced, but anterior cerebellar activation during a simple motor task was normal or even greater than normal [66•], paralleling postmortem reports of substantial Purkinje neuron loss in the posterior but not anterior cerebellum [67].

Conclusion

A general pattern of brain maldevelopment in autism emerges from the past and recent literature: (1) Neural maldevelopment begins during prenatal or early postnatal life; (2) abnormally accelerated brain growth marks the first two years of life, but this gives way to a slower rate of change including arrest of growth in some structures; and (3) sometime between approximately 5 and 12 years of age the sizes of structures within the normal brain eventually catch up with and equal or exceed those in the autistic brain.

The neuronal explanation for the early brain overgrowth in autism in the first years of life and the slowed growth rates between approximately 5 and 12 years of age is unknown. However, evidence from the 5-year-old to adult autistic brain suggests that neurons are small, minicolumns are narrow and underdeveloped, efficacy is reduced for at least some neurotransmitter systems, anti-apoptotic molecular factors are reduced, local and thalamocortical interactions may be aberrant, and con-

nectivity is abnormal. One hypothesis is that the underlying abnormality is an excessive number of cortical minicolumns and axonal projections associated with each minicolumn. This would explain excessive gray as well as excessive white matter volumes at early developmental stages. If these are dysfunctional, however, eventually reduced growth and loss of synapses, axonal collaterals, and neurons would be manifested as slowed white and gray matter growth, small cell size, underdeveloped minicolumns, reduced *N*-acetylaspartate, and abnormal white matter diffusion patterns. However, the hypothesis that there are an excessive number of minicolumns in the autistic cerebral cortex remains to be further stereologically and systematically tested and demonstrated.

Volumetric, metabolic, histological, molecular, and functional abnormalities in the autistic brain – particularly in the young brain – are most marked in the cerebellum, frontal lobes, temporal lobes and limbic system, and both gray and white matter deviations are present. Therefore, the neural systems that are most abnormal include those that are especially vital for higher-order integration, selection and feedback control over lower-order systems. Early developmental abnormality in these multiple higher-order systems explains why autism is a pervasive disorder affecting multiple neurobehavioral domains. Courchesne and Pierce [68] raised the new hypothesis that pivotal to autism is the underdevelopment of large integrative and projecting pyramidal neurons, most especially those in frontal cortex. They argued that these neurons would be especially vulnerable to early abnormal growth because normally their structural and functional elaboration requires many years to be completed in the human [69]. Underdevelopment of large frontal pyramidal neurons would result in reduced long distance anterior to posterior cortico-cortical connectivity and increased local and short-distance cortical connectivity. Such long distance underconnectivity but local overconnectivity is compatible with recent DTI, fMRI and white matter volume results. In the frontal cortex, for example, spindle neurons, a distinct type of pyramidal neuron, are evolutionarily new inventions [70] thought to be involved in higher-order socio-emotional and other cognitive functions [71], integrating information from and projecting to widespread functional domains in the brain. They appear developmentally in the first years of life [71], approximately when the early brain overgrowth process in autism occurs. The underdevelopment of these as well as other large frontal pyramidal neurons may be a critical event in the developmental derailment of socio-emotional and other higher-order functions in autism [68].

From current evidence, autism must be caused by prenatal or early postnatal events. Candidate genetic and

non-genetic factors have been suggested, and multiple factors with complex interactions may be causal of autism. Molecular, neuronal, system and regional abnormalities, as well as an unusual pattern of age-related growth abnormalities have been identified in autism, and these collectively provide characteristics needed for endophenotype-guided etiological as well as animal model studies of the disorder.

Future research aimed at studying the biological precursors to the development of autism, before the complete manifestation of the neural and behavioral phenotype, is needed. Such studies will be able to test the hypothesis that neural and behavioral outcome in autistic infants may be related to various parameters of the overgrowth process, including age of onset, rate, magnitude and age of cessation. Addressing this early aberrant growth process will undoubtedly provide exciting new discoveries in the field, leading to a realistic hope for the prevention of this disorder.

Acknowledgements

The authors are supported by funds awarded to E.C. from the National Institute of Mental Health (2-ROI-MH36840-19) and National Institute of Neurological Disorders and Stroke (2-ROI-NS19855-19).

References and recommended reading

Papers of particular interest, published within the annual period of review, have been highlighted as:

- of special interest
- of outstanding interest

- 1 Kanner L. Autistic disturbances of affective contact. *Nervous Child* 1943; 2:217–250.
- 2 Lord C, Risi S. Diagnosis of autism spectrum disorders in young children. In: Wetherby A, Prizant B, editors. *Autism spectrum disorders: a transactional developmental perspective*. Baltimore: Paul H. Brookes Publishing Co.; 2000. pp. 167–190.
- 3 Courchesne E, Pierce K. Autism. In: Ramachandran VS, editor. *Encyclopedia of the human brain*. San Diego: Academic Press; 2002. pp. 341–344.
- 4 Dawson G, Osterling J, Meltzoff AN, Kuhl, P. Case study of the development of an infant with autism from birth to 2 years of age. *J Appl Dev Psychol* 2000; 21:299–213.
- 5 Maestro S, Muratori F, Cavallaro MC, *et al.* Attentional skills during the first 6 months of age in autism spectrum disorder. *J Am Acad Child Adolesc Psychiatry* 2002; 41:1239–1245.
- 6 Adrien JL, Lenoir P, Martineau J, *et al.* Blind ratings of early symptoms of autism based upon family home movies. *J Am Acad Child Adolesc Psychiatry* 1993; 32:617–626.
- 7 Osterling J, Dawson G. Early recognition of children with autism: a study of first birthday home videotapes. *J Autism Dev Disord* 1994; 24:247–257.
- 8 Courchesne E. Brainstem, cerebellar and limbic neuroanatomical abnormalities in autism. *Curr Opin Neurobiol* 1997; 7:269–278.
- 9 Belmonte M, Cook EH Jr, Anderson GM, *et al.* Autism as a disorder of neural information processing: directions for research and targets for therapy. *Mol Psychiatry* 2004; in press.
- 10 Lipkin WI, editor. Microbiology, immunology and toxicology of autism and other neurodevelopmental disorders. *Mol Psychiatry* 2002; 7 (Suppl. 2):S2–S52.
- 11 Greicius MD. Neuroimaging in developmental disorders. *Curr Opin Neurol* 2003; 16:143–146.
- 12 Bartholomeusz HH, Courchesne E, Karns C. Relationship between head circumference and brain volume in healthy normal toddlers, children, and adults. *Neuropediatrics* 2002; 33:239–241.
- 13 Courchesne E, Carper R, Akshoomoff N. Evidence of brain overgrowth in the •• first year of life in autism. *JAMA* 2003; 290:337–344. Retrospective HC measures from children with autistic disorder and PDD–NOS identified a process of pathological brain growth preceding the clinical diagnostic onset of the disorder. Whereas head size is slightly smaller at birth (25th percentile), brain growth rapidly accelerates within the first year of life such that by 6–14 months of age, head circumference measures are at the 84th and 54th percentiles for autistic disorder and PDD–NOS, respectively.
- 14 Courchesne E, Karns C, Davis HR, *et al.* Unusual brain growth patterns in early life in patients with autistic disorder: an MRI study. *Neurology* 2001; 57:245–254.
- 15 Sparks BF, Friedman SD, Shaw DW, *et al.* Brain structural abnormalities in young children with autism spectrum disorder. *Neurology* 2002; 59:184–192.
- 16 Carper RA, Moses P, Tigue ZD, Courchesne E. Cerebral lobes in autism: early hyperplasia and abnormal age effects. *Neuroimage* 2002; 16:1038–1051.
- 17 Levitt JG, Blanton RE, Smalley S, *et al.* Cortical sulcal maps in autism. *Cereb Cortex* 2003; 13:728–735.
- 18 Hashimoto T, Tayama M, Murakawa K, *et al.* Development of the brainstem and cerebellum in autistic patients. *J Autism Dev Disord* 1995; 25:1–18.
- 19 Kaufmann WE, Cooper KL, Mostofsky SH, *et al.* Specificity of cerebellar vermian abnormalities in autism: a quantitative magnetic resonance imaging study. *J Child Neurol* 2003; 18:463–470.
- 20 Levitt J, Blanton R, Capetillo-Cunliffe L, *et al.* Cerebellar vermian lobules VIII–X in autism. *Progress Neuropsychopharmacol Biol Psychiatry* 1999; 23:625–633.
- 21 Araghi-Niknam M, Fatemi SH. Levels of bcl-2 and p53 are altered in superior frontal and cerebellar cortices of autistic subjects. *Cell Mol Neurobiol* 2003; 23:945–952.
- 22 Fatemi SH, Halt AR, Stary JM, *et al.* Reduction in anti-apoptotic protein bcl-2 in autistic cerebellum. *Neuroreport* 2001; 12:929–933.
- 23 Lee M, Martin-Ruiz C, Graham A, *et al.* Nicotinic receptor abnormalities in the cerebellar cortex in autism. *Brain* 2002; 125:1483–1495.
- 24 Carper RA, Courchesne E. Inverse correlation between frontal lobe and cerebellum sizes in children with autism. *Brain* 2000; 123:836–844.
- 25 Akshoomoff N, Lord C, Lincoln AJ, *et al.* Outcome classification of preschool children with autism spectrum disorders using MRI brain measures. *J Am Acad Child Adolesc Psychiatry* 2004; 43:349–357.
- 26 Kates WR, Burnette CP, Eliez S, *et al.* Neuroanatomic variation in monozygotic twin pairs discordant for the narrow phenotype for autism. *Am J Psychiatry* 2004; 161:539–546.
- 27 Herbert MR, Ziegler DA, Deutsch CK, *et al.* Dissociations of cerebral cortex, subcortical and cerebral white matter volumes in autistic boys. *Brain* 2003; 126:1182–1192.
- 28 Hardan AY, Kilpatrick M, Keshavan MS, Minshew NJ. Motor performance and anatomic magnetic resonance imaging (MRI) of the basal ganglia in autism. *J Child Neurol* 2003; 18:317–324.
- 29 Tsatsanis KD, Rourke BP, Klin A, *et al.* Reduced thalamic volume in high-• functioning individuals with autism. *Biol Psychiatry* 2003; 53:121–129. In this study a linear positive relationship normally seen between the thalamic and whole brain volume was absent in the autistic group. This finding suggests that the development of thalamo-cortical connections may be abnormal, but such a claim would require further research.
- 30 Rojas DC, Bawn SD, Benkers TL, *et al.* Smaller left hemisphere planum temporale in adults with autistic disorder. *Neurosci Lett* 2002; 328(3):237–240.
- 31 Aylward EH, Minshew NJ, Field K, *et al.* Effects of age on brain volume and head circumference in autism. *Neurology* 2002; 59:175–183.
- 32 Rosenbloom S, Campbell M, George AE, *et al.* High resolution CT scanning in infantile autism: A quantitative approach. *J Am Acad Child Psychiatry* 1984; 23(1):72–77.
- 33 Creasey H, Rumsey JM, Schwartz M, *et al.* Brain morphometry in autistic men as measured by volumetric computed tomography. *Arch Neurol* 1986; 43(7):669–672.
- 34 Jacobson R, Le Couteur A, Howlin P, Rutter M. Selective subcortical abnormalities in autism. *Psychol Med* 1988; 18(1):39–48.
- 35 Gaffney GR, Kuperman S, Tsai LY, Minchin S. Forebrain structure in infantile autism. *J Am Academy Child Adolesc Psychiatry* 1989; 28(4):534–537.
- 36 Aylward E, Minshew N, Goldstein G, *et al.* MRI volumes of amygdala and hippocampus in non-mentally retarded autistic adolescents and adults. *Neurology* 1999; 53:2145–2150.

- 37 Haznedar MM, Buchsbaum MS, Wei TC, *et al.* Limbic circuitry in patients with autism spectrum disorders studied with positron emission tomography and magnetic resonance imaging. *Am J Psychiatry* 2000; 157:1994–2001.
- 38 Courchesne E, Muller R-A, Saitoh O. Brain weight in autism: normal in the majority of cases, megalencephalic in rare cases. *Neurology* 1999; 52:1057–1059.
- 39 Lotspeich LJ, Kwon H, Schumann CM, *et al.* Investigation of neuroanatomical differences between autism and Asperger syndrome. *Arch Gen Psychiatry* 2004; 61(3):291–298.
- 40 Bigler ED, Tate DF, Neeley ES, *et al.* Temporal lobe, autism, and macrocephaly. *AJNR Am J Neuroradiol* 2003; 24(10):2066–2076.
- 41 Pierce K, Müller R-A, Ambrose J, *et al.* Face processing occurs outside the fusiform 'face area' in autism: Evidence from fMRI. *Brain* 2001; 124:2059–2073.
- 42 Herbert MR, Ziegler DA, Makris N, *et al.* Localization of white matter volume increase in autism and developmental language disorder. *Ann Neurol* 2004; 55(4):530–540.
- 43 Conciatori M, Stodgell CJ, Hyman SL, *et al.* Association between the HOXA1 A218G polymorphism and increased head circumference in patients with autism. *Biol Psychiatry* 2004; 55:413–419.
- 44 Nelson KB, Grether JK, Croen LA, *et al.* Neuropeptides and neurotrophins in neonatal blood of children with autism or mental retardation. *Ann Neurol* 2001; 49:597–606.
- 45 Gharani N, Benayed R, Mancuso V, *et al.* Association of the homeobox transcription factor, ENGRAILED 2, with autism spectrum disorder. *Mol Psychiatry* 2004; 9(5):474–484.
- 46 Kemper T, Bauman M. Neuropathology of infantile autism. *J Neuropath Exp Neurol* 1998; 57:645–652.
- 47 Bailey A, Luthert P, Dean A, *et al.* A clinicopathological study of autism. *Brain* 1998; 121:889–905.
- 48 Allen G, Buxton RB, Wong EC, Courchesne E. Attentional activation of the cerebellum independent of motor involvement. *Science* 1997; 275(5308):1940–1943.
- 49 Courchesne E, Allen G. Prediction and preparation, fundamental functions of the cerebellum. *Learn Mem* 1997; 4(1):1–35.
- 50 Levisohn L, Cronin-Golomb A, Schmahmann JD. Neuropsychological consequences of cerebellar tumour resection in children: Cerebellar cognitive affective syndrome in a pediatric population. *Brain* 2000; 123 (Pt 5):1041–1050.
- 51 Pierce K, Courchesne E. Evidence for a cerebellar role in reduced exploration and stereotyped behavior in autism. *Biol Psychiatry* 2001; 49:655–64.
- 52 Hornig M, Mervis R, Hoffman K, Lipkin WI. Infectious and immune factors in neurodevelopmental damage. *Mol Psychiatry* 2002; 7 Suppl 2:S34–35.
- 53 Patterson PH. Maternal infection: window on neuroimmune interactions in fetal brain development and mental illness. *Curr Opin Neurobiol* 2002; 12:115–118.
- 54 Fatemi SH, Earle J, Kanodia R, *et al.* Prenatal viral infection leads to pyramidal cell atrophy and macrocephaly in adulthood: implications for genesis of autism and schizophrenia. *Cell Mol Neurobiol* 2002; 22:25–33.
- In the first animal model of autism that encompasses developmental brain growth abnormalities, the authors found that prenatal influenza exposure in mice produces many of the neuroanatomical features of autism, including small brain size at birth, but macrocephaly in adulthood, altered neuronal cell density, and atrophy of pyramidal cell size. A companion paper [55*] demonstrated that behavioral abnormalities in these mice are similar to the autism phenotype.
- 55 Shi L, Fatemi SH, Sidwell RW, Patterson PH. Maternal influenza infection causes marked behavioral and pharmacological changes in the offspring. *J Neurosci* 2003; 23:297–302.
- In this study, prenatal influenza exposure in mice produced many of the behavioral features of autism, including reduced exploration, deficient social interactions, and reduced prepulse inhibition. Furthermore, the authors have suggestive evidence that these abnormalities may be caused by the maternal immune response, rather than the influenza virus itself. A companion paper [54**] demonstrated that these mice have neuroanatomical features similar to those seen in autism.
- 56 Friedman SD, Shaw DW, Artru AA, *et al.* Regional brain chemical alterations in young children with autism spectrum disorder. *Neurology* 2003; 60:100–107.
- The authors used MRS to test the specific hypothesis of increased cell density in 3–4-year-old children with enlarged brains.
- 57 Levitt JG, O'Neill J, Blanton RE, *et al.* Proton magnetic resonance spectroscopic imaging of the brain in childhood autism. *Biol Psychiatry* 2003; 54(12):1355–1366.
- 58 Hisaoka S, Harada M, Nishitani H, Mori K. Regional magnetic resonance spectroscopy of the brain in autistic individuals. *Neuroradiology* 2001; 43:496–498.
- 59 Otsuka H, Harada M, Mori K, *et al.* Brain metabolites in the hippocampus-amygdala region and cerebellum in autism: a 1H-MR spectroscopy study. *Neuroradiology* 1999; 41:517–519.
- 60 Chugani DC, Sundram BS, Behen M, *et al.* Evidence of altered energy metabolism in autistic children. *Prog Neuropsychopharmacol Biol Psychiatry* 1999; 23:635–641.
- 61 Casanova MF, Buxhoeveden DP, Switala AE, Roy E. Minicolumnar pathology in autism. *Neurology* 2002; 58:428–432.
- 62 Barnea-Goraly N, Kwon H, Menon V, *et al.* White matter structure in autism: preliminary evidence from diffusion tensor imaging. *Biol Psychiatry* 2004; 55:323–326.
- Using DTI, the authors provide the first report of white matter tract structure and coherence in autism. Preliminary evidence reveals abnormalities in the anterior corpus callosum extending into the medial prefrontal cortex, medial and lateral temporal lobes, including the temporo-parietal junction and centrum seivole.
- 63 Belmonte MK, Yurgelun-Todd DA. Functional anatomy of impaired selective attention and compensatory processing in autism. *Brain Res Cogn Brain Res* 2003; 17:651–664.
- A functional MRI study of patients with ASD during a visual selective attention task demonstrates reduced activity in the frontal, parietal, and temporal regions, but increased activity in the occipital region. This study is one of the clearest examples of an emerging pattern of functional abnormalities in autism, namely reduced frontal, but enhanced posterior, activity.
- 64 Hubl D, Bolte S, Feineis-Matthews S, *et al.* Functional imbalance of visual pathways indicates alternative face processing strategies in autism. *Neurology* 2003; 61:1232–1237.
- 65 Castelli F, Frith C, Happe F, Frith U. Autism, Asperger syndrome and brain mechanisms for the attribution of mental states to animated shapes. *Brain* 2002; 125 (Pt 8):1839–1849.
- 66 Allen G, Courchesne E. Differential effects of developmental cerebellar abnormality on cognitive and motor functions in the cerebellum: an fMRI study of autism. *Am J Psychiatry* 2003; 160:262–273.
- Performance and functional activity during an attentional task were correlated with the area of right superior cerebellar hemisphere lobule VIIa in autistic individuals. This is one of the few studies to examine anatomical, functional, and behavioral correlates in autism.
- 67 Bauman ML, Kemper TL, editors. Neuroanatomic observations of the brain in autism. In: *The neurobiology of autism*. Baltimore: Johns Hopkins University Press; 1994. pp. 119–145.
- 68 Courchesne E, Pierce K. Early brain overgrowth in autism: A potential signal of disrupted development of frontal pyramidal neurons and connectivity. *Int J Dev Neurosci* 2004; in press.
- 69 Huttenlocher P. Neural Plasticity: The effects of environment on the development of the cerebral cortex. Harvard University Press, Cambridge, MA, 2002; chapters 1 and 2.
- 70 Nimchinsky EA, Gilissen E, Allman JM, *et al.* A neuronal morphologic type unique to humans and great apes. *Proc Natl Acad Sci U S A* 1999; 96:5268–5273.
- 71 Allman JM, Hakeem A, Erwin JM, *et al.* The anterior cingulate cortex. The evolution of an interface between emotion and cognition. *Ann NY Acad Sci* 2001; 935:107–117.